

The Eurasia Proceedings of Health, Environment and Life Sciences (EPHELS), 2024

Volume 13, Pages 82-87

ICGeHeS 2024: International Conference on General Health Sciences

SLC5A6 Gene Mutations Associated with Developmental Delay in a Child: Case Report

Victoria Kononets

West Kazakhstan Marat Ospanov Medical University

Gulmira Zharmakhanova

West Kazakhstan Marat Ospanov Medical University

Lyazzat Syrlybayeva

West Kazakhstan Marat Ospanov Medical University

Eleonora Nurbaulina

West Kazakhstan Marat Ospanov Medical University

Abstract: Sodium-dependent multivitamin transporter (SMVT) deficiency is a recently described multivitamin-dependent inherited metabolic disorder (IMD). SMVT is encoded by the SLC5A6 gene located on chromosome 2p23.3. We describe a clinical case of SMVT deficiency in a child with developmental delay, microcephaly, persistent neurological symptoms, skin lesions and frequent upper respiratory tract infections. A tandem mass spectrometry study of the metabolic profile of amino acids and acylcarnitines, carried out twice, showed increased blood levels of methylmalonylcarnitine + 3-hydroxyisovalerylcarnitine (C4DC/C5OH). Urine analysis by gas chromatography-mass spectrometry showed persistently increased excretion of 3-OH-isovaleric acid. The combination of increased blood concentrations of C4DC/C5OH and increased urinary excretion of 3-OH-isovaleric acid suggested a metabolic disorder associated with impaired biotin metabolism. Determination of the level of biotinidase in the blood did not reveal deviations from the reference values. Biotin was prescribed. As a result of clinical exome sequencing, complex heterozygous variants of the SLC5A6 gene encoding SMVT were identified. The patient was treated with increased doses of oral biotin, pantothenic acid, and lipoic acid, which resulted in significant clinical improvement.

Keywords: SLC5A6, SMVT, Biotin, Pantothenic acid, Lipoic acid

Introduction

The sodium-dependent multivitamin transporter, which facilitates the absorption of the water-soluble vitamins biotin, pantothenic acid, and the vitamin-like substance lipoate, is encoded by the SLC5A6 gene. Mutations in this gene cause an extremely rare and poorly understood metabolic disorder (Schwantje et al., 2019; Hauth et al., 2022). The Na(+)/multivitamin transporter (SMVT) is a member of the sodium solute symporter family that catalyzes the Na(+)-dependent absorption of the structurally diverse water-soluble vitamins, pantothenic acid (vitamin B5) and biotin (vitamin H).), α -lipoic acid - a vitamin-like substance with strong antioxidant properties and iodide (Quick & Shi, 2015).

The transporter-mediated transport process is activated by the transmembrane sodium ion gradient as well as by the membrane potential. The transporter belongs to the sodium-coupled glucose transporter family (Figure 1). The ubiquitous expression of this transporter in mammalian tissues and the fact that it is highly conserved across species indicate the significance and importance of this transporter (Prasad & Ganapathy, 2000).

- This is an Open Access article distributed under the terms of the Creative Commons Attribution-Noncommercial 4.0 Unported License, permitting all non-commercial use, distribution, and reproduction in any medium, provided the original work is properly cited.

- Selection and peer-review under responsibility of the Organizing Committee of the Conference

©2024 Published by ISRES Publishing: www.isres.org

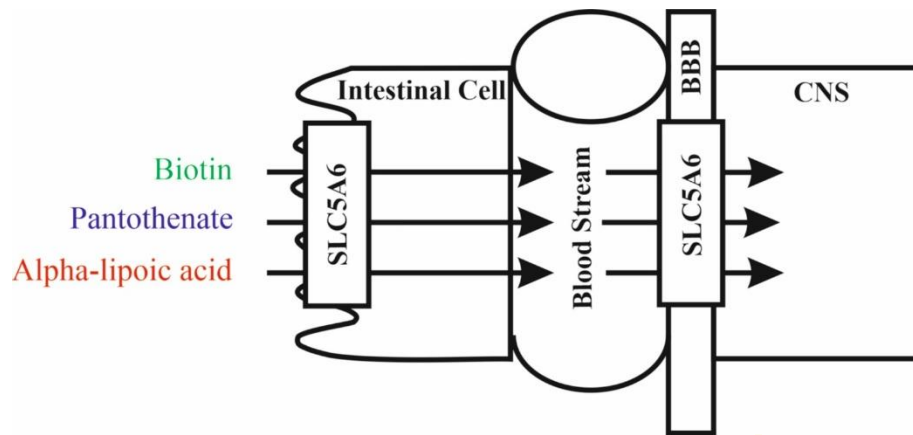


Figure 1. SCL5A6 function. *BBB* blood–brain barrier.

SMVT has been found in many types of tissues, including liver, kidney, and placenta tissues (Quick & Shi, 2015). Organic SMVT substrates play a central role in cellular metabolism and are therefore essential for normal human health and development. SMVT is the only biotin transport system active in the intestine, and its knockout results in biotin deficiency (Ghosalet et al., 2013; Sabui et al., 2018).

Biotin (vitamin B7) serves as an activating cofactor for five carboxylases involved in various metabolic reactions, including fatty acid synthesis, gluconeogenesis, and amino acid catabolism (Figure 2) (Baumgartner & Suormala, 2016). Biotin deficiency leads to stunting, dermatological disorders and neurological disorders (Quick & Shi, 2015; de Carvalho & Quick, 2011; Holling et al., 2022).

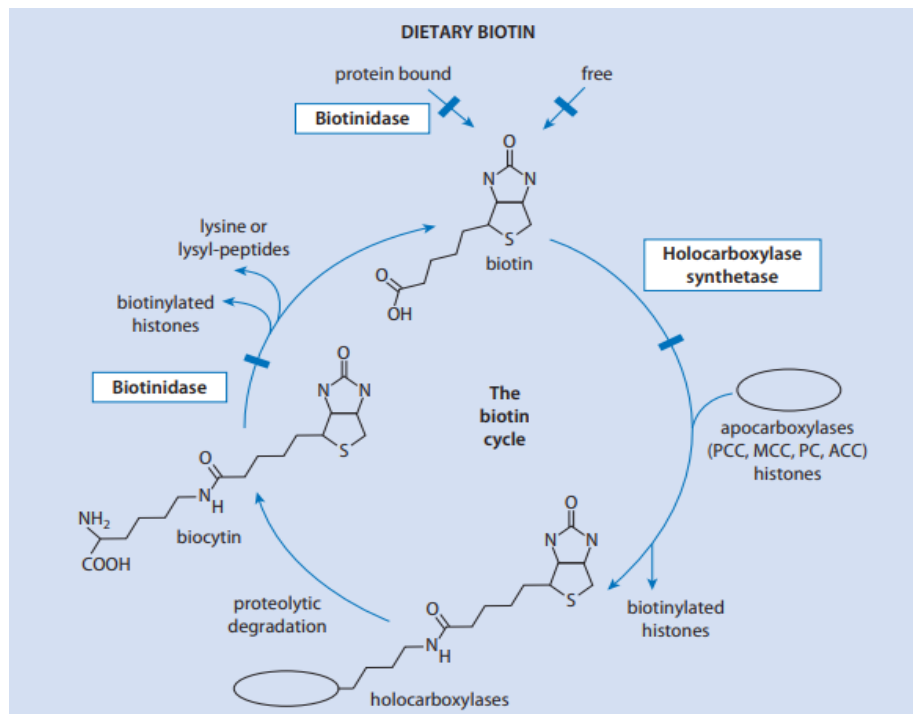


Figure 2. The biotin cycle. Sites of the enzyme and transport defects are indicated by solid bars. *ACC*, acetyl-CoA carboxylases (*ACC-1*, cytosolic; *ACC-2*, outer mitochondrial membrane); *MCC*, 3-methylcrotonyl-CoA carboxylase; *PC*, pyruvate carboxylase; *PCC*, propionyl-CoA carboxylase. (Baumgartner & Suormala, 2016).

Pantothenic acid is a precursor of coenzyme A, therefore, a deficiency of pantothenic acid can lead to limited availability of coenzyme A. Coenzyme A acts as a cofactor of enzymes involved in the tricarboxylic acid cycle and fatty acid metabolism (Miallot et al., 2023). Lipoate is one of the cofactors in the glycine cleavage system and pyruvate dehydrogenase, branched chain ketoacid dehydrogenase and ketoglutarate dehydrogenase complexes. These enzymes catalyze redox reactions in the production of mitochondrial energy and provide oxidative decarboxylation reactions of amino acids and ketoacids (Van Hove, Hennerman & Coughlin, 2016). In addition to its function as a cofactor, lipoate may also have antioxidant and anti-inflammatory effects. In

addition to facilitating the absorption of biotin, pantothenic acid and lipoate, SMVT is capable of transporting iodide and therefore possibly also influences iodide homeostasis in the body (de Carvalho & Quick, 2011) (Figure 3).

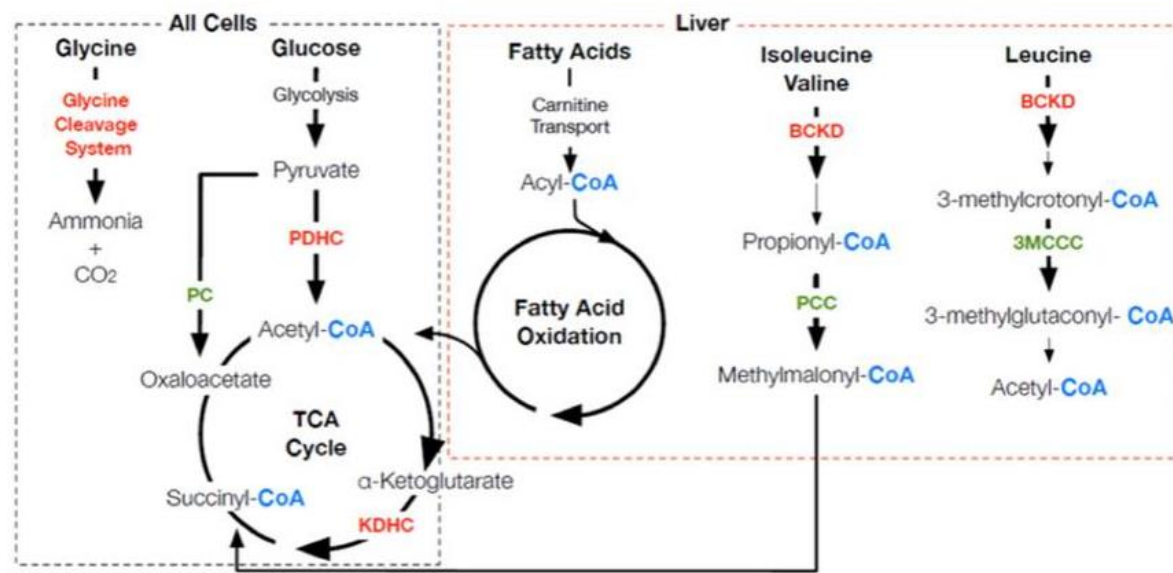


Figure 3. Biotin, pantothenate and lipoate-dependent metabolic pathways and the effect of identified variants in SLC5A6. Enzymes for which the vitamins Biotin (green), Pantothenate (blue) and Alpha-lipoic acid (red) play a role as important cofactors in: the degradation pathways of the amino acids leucine, isoleucine, valine and glycine; glucose energy metabolism; the TCA cycle; and fatty acid oxidation metabolism. BCKD Branch chain ketoacid dehydrogenase, CNS central nervous system, KDHC ketoglutarate dehydrogenase complex, PC pyruvate carboxylase, PCC propionyl-CoA carboxylase, PDHC pyruvate dehydrogenase complex, 3MCCC 3-methyl crotonyl-CoA carboxylase (Byrne et al., 2019).

The gene encoding SMVT, SLC5A6, is located on chromosome 2. Variants leading to disruption of SMVT protein function may result in intracellular deficiency of its organic substrates, as it is the only known combined transporter of biotin, pantothenic acid and lipoates (Quick & Shi, 2015). Given their metabolic functions, intracellular deficiencies of biotin, pantothenic acid and lipoate can cause a wide range of signs and symptoms.

Holling et al. (2022) reported complex heterozygous variants of SLC5A6 in people with various multisystem diseases, including developmental delay, developmental delay, seizures, cerebral palsy, brain atrophy, gastrointestinal problems, immunodeficiency, and/or osteopenia. Holling et al. (2022) identified the homozygous variant c.1285 A > G [p.(Ser429Gly)] in three affected siblings and a simplex patient, as well as the maternally inherited variant c.280 C > T [p.(Arg94*)] and inherited paternal line option c.485 option A > G [p.(Tyr162Cys)] in a simplex patient of the third family. Subramanian et al. (2017) reported the identification of mutations R94X (premature termination) and R123L (dysfunctional amino acid change) in exon 3 of the SLC5A6 gene in a child using a genome-wide scan. Variants of the SLC5A6 gene can lead to metabolic disorders that mimic biotinidase deficiency, which can be treated with supplements of the vitamins biotin and pantothenic acid (Schwantje et al., 2019; Sabui et al., 2018).

Case report

The patient, a 2-year-old girl, is the first child of healthy, unrelated parents. She was born full term, at 39 weeks, after an uncomplicated pregnancy. The Apgar score was 7 at 1 minute and 8 at 5 minutes. Her weight at birth was 3.4 kg, height 54 cm. She screamed immediately after birth and attached to the breast on the 1st day. The breast sucked actively. There were no dysmorphic features at birth. The child's nutrition throughout the year is breastfeeding.

Growth and development were normal during the neonatal period. However, in the first year of the child's life, frequent colds with symptoms of respiratory failure and delayed physical, motor and psycho-speech development were noted. Also, during the first year of life, low hemoglobin levels, lesions of the facial skin, conjunctiva, cheilitis, cracks in the corners of the mouth, and hair loss were noted. She was repeatedly

hospitalized in infectious diseases and multidisciplinary hospitals. She suffered from bronchitis, pneumonia and was admitted to the intensive care unit several times with signs of respiratory failure.

At the age of 12 months after the third hospitalization, she was examined by a hospital neurologist. Neurological status: Level of consciousness - clear. Round head, microcephaly. The palpebral fissures are symmetrical D=S, the pupils are narrow D=S. Full movement of the eyeballs. The pupils react to light. The face is symmetrical, the tongue is in the midline. Swallowing and phonation were preserved. Muscle tone is normal. Tendon reflexes: increased, expansion of reflexogenic zones. Babinski's sign is positive on both sides. Pathological foot signs are positive. Meningeal signs are negative. Psychomotor and physical development: holds his head from 3 months, turns from side to side from 4 months, sits from 6 months, does not crawl, does not walk. A CT scan of the brain at the age of 12 months revealed cysts of the septum pellucida, periventricular leukomalacia of both cerebral hemispheres, non-occlusive internal hydrocephalus, and signs of bilateral mesotympanitis.

The audiologist's examination revealed no pathology. An examination by an optometrist at the age of 20 months revealed bilateral optic nerve atrophy and keratopathy. Heredity, according to my mother, is burdened by the birth of children with Down syndrome from paternal and maternal great-aunts. Due to constant recurrent infectious diseases, inflammation around natural orifices, developmental delays, low weight gain, anemia (hemoglobin 79 g/l), microcephaly, and non-growing hair, a suspicion of hereditary metabolic diseases arose. The child was referred for consultation to a geneticist; if hereditary metabolic diseases were suspected, it was recommended to undergo examination using tandem mass spectrometry (MS/MS) and karyotyping. At the age of 20 months, she had developmental delay with inability to move independently and impaired intellectual development with severe speech delay. Karyotyping revealed a karyotype of 46 XX; no chromosomal pathology was detected.

The results of determining the amino acid and acylcarnitine profile by MS/MS at the age of 14 months revealed an increase in the blood concentration of methylmalonylcarnitine + 3-hydroxyisovalerylcarnitine (C4DC/C5OH) to 2.7 µmol/L (upper limit: 0.9 µmol/L). Urine analysis showed elevated excretion of 3-OH-isovaleric acid (604 mmol/mol creatinine; upper limit: 67 mmol/mol creatinine). A repeat MS/MS analysis performed at the age of 15 months also revealed an increase in methylmalonylcarnitine+3-hydroxyisovalerylcarnitine (C4DC/C5OH) in the blood to 3.22 µmol/L. The combination of increased blood concentrations of C4DC/C5OH and increased urinary excretion of 3-OH-isovaleric acid suggested a metabolic disorder associated with impaired biotin metabolism (beta ketothiolase deficiency, multiple carboxylase deficiency, and biotinidase deficiency). Determination of the level of biotinidase in the blood (5.80 nmol/min/ml) did not reveal deviations from the reference values (4.40 - 12.00 nmol/min/ml). However, clinical symptoms and biochemical analysis indicated biotin deficiency. Therefore, from December 2022, pathogenetic treatment was prescribed - taking biotin in a daily dose of 10 mg per day. While taking biotin, positive dynamics were noted - hair began to grow, dry skin disappeared, signs of severe conjunctivitis disappeared, cheilitis disappeared, the concentration of hemoglobin in the blood increased to 119 g/l.

The child's blood samples were sent for confirmatory molecular genetic analysis using Clinical exome sequencing (CES). DNA analysis was carried out using next-generation sequencing technology using the paired-end reading method. For sample preparation, a technique was used to selectively capture DNA sections related to the coding regions of genes with known clinical significance (clinical exome) or genes associated with a group of diseases and described in the curated OMIM database. The method allows you to identify inherited or newly emerged (de novo) variants of the nucleotide sequence (single-nucleotide substitutions, small insertions and deletions - up to 10 base pairs), which can cause a genetic disease. As a result of the sequencing of the clinical exome, complex heterozygous variants of the gene encoding SMVT were identified (Table 1).

Table 1. Variants of the SLC5A6 gene encoding SMVT and having significant signs of pathogenicity

Gene	Chromosome	Genome assembly GRCh38 (hg38)	HGVS reference	DNA	HGVS protein reference	Variant type	Predicted effect	Genotype	ClinVar ID
SLC5A6	2	chr2:27207441	c.209delC		p.Pro70fs 206	Deletion	Deletion	Heterozygous	ENST00000310574
SLC5A6	2	chr2:27207618	c.31_32delCT		p.Leu11fs 196	Deletion	Deletion	Heterozygous	ENST00000310574

The SLC5A6 gene variants listed in Table 1 have been described as pathogenic, leading to frameshifts. These variants are not available in the EXAC, GNOMAD, and GENOMED population databases. The detected heterozygous variants in trans position are described as a possible cause of the disease.

Thus, mutations in the SLC5A6 gene, encoding SMVT, led to the formation of clinical signs of biotin deficiency, and the insufficient effectiveness of biotin therapy was explained by the involvement in the process, in addition to biotin, of pantothenic acid, lipoic acid and iodide. Based on this diagnosis, our patient was started on increased oral doses of biotin, pantothenic acid, and lipoic acid at dosage levels of 15, 300, and 200 mg per day, respectively. Doses were then increased at 24 months of age to 30 mg/day, 500 mg/day, and 300 mg/day, respectively. The child's motor skills have improved. Verbal skills have also improved when pronouncing a few simple words. Weight and height reached normal levels, manifestations of microcephaly became less pronounced. The condition of the skin and mucous membranes has improved significantly, hair growth has been restored.

The child's positive response to high pharmacological doses of these vitamins confirms that dysfunction of SMVT is the cause of the observed clinical picture. Uptake of biotin, pantothenic acid and lipoic acid into various cells at high pharmacological concentrations also occurs through simple diffusion and may, at least partially, reduce the need for a functional SMVT system (Subramanian et al., 2017; Holling et al., 2022), and triple vitamin replacement therapy, likely through a simple diffusion mechanism, had a beneficial effect in patients (Subramanian et al., 2017; Byrne et al., 2019; Schwantje et al., 2019; Holling et al., 2022).

Conclusion

Therefore, the general condition, growth, physical and mental development of the patient improved. A positive response to biotin, pantothenic acid and lipoic acid confirms the clinical and genetic diagnosis. The practical aspect of identifying mutations in the SLC5A6 gene encoding SMVT in our patient is to confirm the possibility of pharmacological correction of the deficiency of biotin, pantothenic acid and lipoates that occurs in this condition. However, it must be taken into account that treatment should be started as early as possible, before irreversible damage to the nervous system and brain occurs.

Conflicts of Interest

The authors declare no conflict of interest.

Funding

This research was funded by the Science Committee of the Ministry of Science and Higher Education of the Republic of Kazakhstan, grant No. AP14869996.

Scientific Ethics Declaration

The authors declare that the scientific ethical and legal responsibility of this article published in EPHELS Journal belongs to the authors.

Acknowledgements or Notes

* This article was presented as a poster presentation at the International Conference on General Health Sciences (www.icgehes.net) held in Alanya/Turkey on May, 02-05, 2024.

References

- Baumgartner, M.R., Suormala, T. (2016). Biotin-responsive disorders. In J. M. Saudubray, M. R. Baumgartner, J. Walter (Eds.). *Inborn metabolic diseases* (pp.375-383). Berlin: Springer.
- Byrne, A. B., Arts, P., Polyak, S. W., Feng, J., Schreiber, A. W., Kassahn, K. S., Hahn, C. N., Mordaunt, D. A., Fletcher, J. M., Lipsett, J., Bratkovic, D., Booker, G. W., Smith, N. J., & Scott, H. S. (2019). Identification and targeted management of a neurodegenerative disorder caused by biallelic mutations in SLC5A6. *NPJ Genomic Medicine*, 4, 28.

- de Carvalho, F. D., & Quick, M. (2011). Surprising substrate versatility in SLC5A6: Na⁺-coupled I⁻ transport by the human Na⁺/multivitamin transporter (hSMVT). *The Journal of Biological Chemistry*, 286(1), 131–137.
- Ghosal, A., Lambrecht, N., Subramanya, S. B., Kapadia, R., & Said, H. M. (2013). Conditional knockout of the Slc5a6 gene in mouse intestine impairs biotin absorption. *American Journal of Physiology. Gastrointestinal and Liver Physiology*, 304(1), G64–G71.
- Hauth, I., Waterham, H. R., Wanders, R. J. A., van der Crabben, S. N., & van Karnebeek, C. D. M. (2022). A mild case of sodium-dependent multivitamin transporter (SMVT) deficiency illustrating the importance of treatment response in variant classification. *Cold Spring Harbor Molecular Case Studies*, 8(2), a006185.
- Holling, T., Nampoothiri, S., Tarhan, B., Schneeberger, P. E., Vinayan, K. P., Yesodharan, D., Roy, A. G., Radhakrishnan, P., Alawi, M., Rhodes, L., Girisha, K. M., Kang, P. B., & Kutsche, K. (2022). Novel biallelic variants expand the SLC5A6-related phenotypic spectrum. *European Journal of Human Genetics : EJHG*, 30(4), 439–449.
- Mayr, J. A., Feichtinger, R. G., Tort, F., Ribes, A., & Sperl, W. (2014). Lipoic acid biosynthesis defects. *Journal of Inherited Metabolic Disease*, 37(4), 553–563.
- Miallot, R., Millet, V., Galland, F., & Naquet, P. (2023). The vitamin B5/coenzyme A axis: A target for immunomodulation?. *European Journal of Immunology*, 53(10), e2350435.
- Prasad, P. D., & Ganapathy, V. (2000). Structure and function of mammalian sodium-dependent multivitamin transporter. *Current Opinion in Clinical Nutrition and Metabolic Care*, 3(4), 263–266.
- Quick, M., & Shi, L. (2015). The sodium/multivitamin transporter: a multipotent system with therapeutic implications. *Vitamins and Hormones*, 98, 63–100.
- Sabui, S., Kapadia, R., Ghosal, A., Schneider, M., Lambrecht, N. W. G., & Said, H. M. (2018). Biotin and pantothenic acid oversupplementation to conditional SLC5A6 KO mice prevents the development of intestinal mucosal abnormalities and growth defects. *American Journal of Physiology. Cell Physiology*, 315(1), C73–C79.
- Schwantje, M., de Sain-van der Velden, M., Jans, J., van Gassen, K., Dorrepaal, C., Koop, K., & Visser, G. (2019). Genetic defect of the sodium-dependent multivitamin transporter: A treatable disease, mimicking biotinidase deficiency. *JIMD Reports*, 48(1), 11–14.
- Subramanian, V. S., Constantinescu, A. R., Benke, P. J., & Said, H. M. (2017). Mutations in SLC5A6 associated with brain, immune, bone, and intestinal dysfunction in a young child. *Human Genetics*, 136(2), 253–261.
- Van Hove, J.L.K., Hennerman, J.B., & Coughlin, H.C.R. (2016). Nonketotic hyperglycinemia (glycine encephalopathy) and lipoate deficiency disorders. In J. M. Saudubray, M. R. Baumgartner, J. Walter (Eds.). *Inborn metabolic diseases* (pp.349-356). Berlin: Springer.
- Zehnpfennig, B., Wiriyaermskul, P., Carlson, D. A., & Quick, M. (2015). Interaction of α -lipoic acid with the human Na⁺/multivitamin transporter (hSMVT). *The Journal of Biological Chemistry*, 290(26), 16372–16382.

Author Information

Victoria Kononets

West Kazakhstan Marat Ospanov Medical University
Maresyev Street 68, Aktobe 030019, Kazakhstan
Contact e-mail: micropaleontolog@yandex.kz

Gulmira Zharmakhanova

West Kazakhstan Marat Ospanov Medical University
Maresyev Street 68, Aktobe 030019, Kazakhstan

Lyazzat Syrlybayeva

West Kazakhstan Marat Ospanov Medical University
Maresyev Street 68, Aktobe 030019, Kazakhstan

Eleonora Nurbaulina

West Kazakhstan Marat Ospanov Medical University
Maresyev Street 68, Aktobe 030019, Kazakhstan

To cite this article:

Kononets, V., Zharmakhanova, G., Syrlybayeva, L., & Nurbaulina, E. (2024). SLC5A6 gene mutations associated with developmental delay in a child: Case report. *The Eurasia Proceedings of Health, Environment and Life Sciences (EPHELs)*, 13, 82-87.